



Treatment of velopharyngeal insufficiency with turn over mucoperiosteal palatal flap in a patient with DiGeorge syndrome

Lečenje velofaringealne insuficijencije primenom prevrnutog mukoperiostnog reznja sa nepca kod bolesnice sa DiGeorge-vim sindromom

Jefta Kozarski*[†], Mila Veselinović[‡], Lazar Djorović*, Biljana Mitrić*,
Ksenija Kozarski[§]

*Military Medical Academy, Clinic for Plastic Surgery and Burns, Belgrade, Serbia;
[†]University of Defence, Faculty of Medicine of the Military Medical Academy, Belgrade, Serbia; [‡]University of Novi Sad, Faculty of Medicine, Department of Special Education and Rehabilitation, Novi Sad, Serbia, [§]Uppsala University, Faculty of Medicine, Uppsala University Hospital Akademiska, Psychiatric Clinic, Uppsala, Sweden

Abstract

Introduction. DiGeorge syndrome (velocardiofacial syndrome) occurs in about 1 in 4,000 people. It is characterized by incomplete gene penetration, due to which there is significant variability in the clinical picture in different patients. The paper describes the successful application of an inverted mucoperiosteal flap of the palate in a nine-year-old girl with DiGeorge syndrome who had pronounced velopharyngeal insufficiency (VPI). **Case report.** The girl was the first-born child from a normal pregnancy and a normal birth with a normal early psychomotor development. During breastfeeding, milk was occasionally returned to the nose, and later deviations from normal speech (incomprehensible and nasal speech) were noticed. At the age of 4, detailed genetic testing was performed and a microdeletion of 22q11 chromosome was found. Also, a submucosal cleft palate was established, and magnetic resonance angiography of the head and neck revealed an abnormal position of the left internal carotid artery (ICA) that extended submucosally to the central axis of the posterior wall of the pharynx. Then, the submucosal cleft palate was surgically resolved in other clinical center, but without speech improvement. Pharyngoplasty was not performed due to the risk of serious post-operative complications. It was explained to the parents that speech recovery will not be satisfactory without surgical treatment of VPI. At the age of 9, the girl was admitted to the Clinic for Plastic and Reconstructive Surgery and Burns of the Military Medical Academy in Belgrade for surgical treatment of VPI. Taking into account the potential risks of

certain surgical methods, it was decided to perform intravelar veloplasty according to Furlow. Since it was intraoperatively found that the soft palate is too short and that this procedure cannot provide its sufficient length, the mucoperiosteal flap was lifted from the palate to the palatal aponeuroses on the posterior edges of the palatine bones leaving their oral surfaces exposed. The mucoperiosteal flap raised in this way could not also provide the required length of the soft palate only by retroposition. However, its length is 160% of the soft palate axis length, which was enough to turn over the front of the flap towards the pharynx of the soft palate to reach its posterior wall. The raised mucoperiosteal palatal flap has no muscles, so its motility was achieved by the fact that along the edges of the existing short and mobile palate, the flap was fixed to the existing palate and uvula. This provided the anatomical preconditions for speech recovery, shown during the one-year post-operative follow-up of the child. Exposed palatine bones and short palate was covered by mucosal tissue, without cystic formations. **Conclusion.** The mucoperiosteal palatal flap can be easily, successfully and maximally safely applied in the resolution of VPI in patients with DiGeorge syndrome where there is an aberrant submucosal position of the ICA. This flap could be a 'flap of choice' for such patients with atopic position of the ISA, too.

Key words:

digorge syndrome; velopharyngeal insufficiency; cleft palate; speech disorders; rehabilitation of speech and language disorders.

Apstrakt

Uvod. DiGeorge-ov sindrom (velokardiofacijalni sindrom) javlja se kod oko 1 od 4 000 ljudi. Karakteriše ga nepotpuna

penetracija gena, zbog čega postoji značajna varijabilnost u kliničkoj slici kod različitih pacijenata. U radu je opisana uspešna primena prevrnutog mukoperiostnog reznja nepca kod devetogodišnje devojčice sa DiGeorge-ovim sindromom.

mom kod koje je postojala izražena velofaringealna insuficijencija (VFI). **Prikaz bolesnika.** Devojčica je prvorodeno dete iz uredne trudnoće i urednog porođaja sa urednim ranim psihomotornim razvojem. Tokom dojenja povremeno je dolazilo do vraćanja mleka na nos, a kasnije je primećeno odstupanje od normalnog govora (nerazumljiv i nazalni govor). U dobi od 4 godine urađeno je detaljno genetičko testiranje i nađena je mikroleucija 22q11 hromozoma. Ustanovljen je i submukozni rascep nepca, a magnetno rezonantnom angiografijom glave i vrata otkrivena je abnormalna pozicija leve unutrašnje karotidne arterije koja se širila submukozno skoro do centralne osovine zadnjeg zida ždrele. Prvo je hirurški rešen submukozni rascep nepca, ali bez poboljšanja govora. Faringoplastika je bila kontraindikovana zbog rizika od ozbiljnih postoperativnih komplikacija. Roditeljima je objašnjeno da bez hirurškog tretmana VFI, oporavak govora neće biti zadovoljavajući. Sa nepunih devet godina devojčica je primljena u Kliniku za plastičnu i rekonstruktivnu hirurgiju i opekotine Vojnomedicinske akademije u Beogradu na hirurško lečenje VFI. Uzimajući u obzir potencijalne rizike od pojedinih hirurških metoda, odlučeno je da se uradi intravelarna veloplastika po Furlow-u. Intraoperativno je utvrđeno da je meko nepce suviše kratko i da ovaj zahvat ne može da obezbedi dovoljno produženje mekog nepca. Zbog toga je odignut mukoperiostni režanj sa nepca do palatalnih aponeuroza na zadnjim ivicama palatalnih kostiju ostavljajući njihove ogoljene oralne površine. Ovako podignut mukoperiostni režanj nije mogao samo re-

ropozicijom da obezbedi potrebnu dužinu mekog nepca. Budući da je ustanovljeno da dužina ovako ispreparisanog reznja iznosi 160% dužine osovine mekog nepca, bilo je dovoljno da se prevrtanjem prednjeg dela reznja ka farinksu mekog nepca, dosegne njegov zadnji zid. Ovaj režanj nema mišiće, pa mu je pokretljivost postignuta tako što je po obodima postojećeg kratkog i pokretnog nepca, režanj fiksiran za postojeće meko nepce i uvulu. Time su bili obezbeđeni anatomske preduslovi za značajan oporavak govora, što je i pokazano tokom jednogodišnjeg postoperativnog praćenja deteta. Ogoljena palatalna kost je bila prekrivena granulacijom, a s vremenom i mukozom, kao na mekom nepcu, bez pojave cističnih formacija. **Zaključak.** Mukoperiostni palatalni režanj se može jednostavno, uspešno i maksimalno bezbedno primenjivati u rešavanju VFI kod pacijenata sa DiGeorge-ovim sindromom gde postoji aberantna submukozna pozicija unutrašnje karotidne arterije, koja doseže skoro do srednje osovine zadnjeg zida farinksa. Opisani režanj i njegova primena pokazuju da on može biti metod izbora u rešavanju VFI kod pacijenata sa DiGeorge-ovim sindromom i aberantnom submukoznom pozicijom unutrašnje karotidne arterije.

Ključne reči:

digeorge sindrom; velofaringealna insuficijencija; nepce, rascep; govor, poremećaji; rehabilitacija poremećaja govora i jezika.

Introduction

American physician Angelo DiGeorge was first described the syndrome in 1968, which in 1981 using genetics was defined as a deletion of a small segment of chromosome 22. This syndrome, known as 22q11.2 deletion syndrome, is inherited autosomally dominantly, with prevalence of 1 in 4,000 people^{1,2}. Diagnosis of DiGeorge syndrome is based on the symptoms and confirmed by genetic testing^{3,4}. Signs and symptoms are as follows: congenital heart disease (40% of individuals), particularly conotruncal malformations [interrupted aortic arch (50%)], persistent *truncus arteriosus* (34%), tetralogy of Fallot, ventricular septal defect, cyanosis, palatal abnormalities (50%), particularly velopharyngeal incompetence, submucosal cleft palate, and cleft palate, characteristic facial features (present in the majority of Caucasian individuals) including hypertelorism, learning difficulties (90%), hypocalcemia (50% – due to hypoparathyroidism), significant feeding problems (30%), renal anomalies (37%), hearing loss, laryngo-trachea-esophageal anomalies, growth hormone deficiency, autoimmune disorders, immune disorders due to reduced T cell numbers, seizures (with or without hypocalcemia), skeletal abnormalities, and psychiatric disorders¹⁻⁵. Current research demonstrates a unique profile of speech and language impairments is associated with 22q11.2DS. The most common problems are hypernasality, language delay, and speech errors, so they are often perform lower on speech and language evaluations in comparison to their nonverbal IQ scores. Hypernasality occurs if air comes

out through the nose during the formation of oral speech sounds, which results in reduced intelligibility. This phenomenon is seen in velopharyngeal insufficiency (VPI), due to the altered structure of the soft palate vellum. Hearing loss can also contribute to increased hypernasality, because children with hearing impairment may have difficulty self-controlling their oral speech⁶⁻⁸.

Case report

A girl, born on May 11, 2009, was the first-born child from a normal pregnancy and a normal birth with a normal early psychomotor development. During breastfeeding, milk was occasionally returned to the nose, and later deviations from normal speech (incomprehensible and nasal speech) were noticed. In April 2011, she was sent to an otorhinolaryngologist-phoniatrician by an audiologist because of incomprehensible and nasal speech. During the first examination, it was revealed nasal speech by type of open nasalization and bad articulation. During the phoniatric examination, VPI was noted with suspected submucosal cleft palate. Suspected DiGeorge syndrome was diagnosed in 2013 in the Clinical Center of Vojvodina, Novi Sad, Serbia. The diagnosis was confirmed by detailed genetic testing in the Institute for Molecular Genetics and Genetic Engineering in Belgrade, in May/June 2013. In 300 (100%) analyzed metaphasis there were found microdeletion of 22q11 chromosome (velocardiofacial syndrome; DiGeorge syndrome). The diagnosis of the submucosal cleft was confirmed at the age of 4 by the use of

flexible nanofiber with optics, at the other Clinical Center. The examination also confirmed the pulsation of a larger blood vessel (carotid artery) on the posterior wall of the pharynx. Magnetic resonance imaging (MRI) angiography of the head and neck was then performed and an abnormal position of the left internal carotid artery (ICA) extending submucosally to the posterior wall of the pharynx was diagnosed (reaching medially from 10 mm to 7 mm from the median axis of the posterior pharyngeal wall) (Figure 1). The right ICA was in the normal position submuscularly. The parents were explained which surgical method should be applied for correction of nasal speech while avoiding possible complications. It was also explained to the mother that the child should be included in speech therapy that would have limited possibilities. In April 2013, speech therapy status was characterized as age-appropriate language skills, but spontaneous speech, although fluent, had significantly impaired articulation and phonation, rhythm and tempo of speech were neat, speech melody was significantly disturbed with monotone voice. Assessment of articulation and discrimination of voices revealed: incorrect pronunciation of all voices and vo-

overlapping toes as low growth. Cardiological examination revealed the aberrant left ventricular horde and mitral valve dysmorphism that were consistent with the described syndrome. Kidney ultrasonography showed a fibrotic band of left kidney with ruptured cysts. Pharyngoplasty was dismissed because of the risk of serious postoperative complications. The mother was explained that the child should be included in speech therapy with limited possibilities. Furthermore, the basic principles of rehabilitation of VPI were also explained, as well as that the rehabilitation would take a long time. The parents were also explained that without surgical treatment of VPI, rehabilitation could not give satisfactory results. In December 2018 (3 months before surgery), speech therapy status was estimated as follows: spontaneous speech – fluent with partially impaired articulation and phonation. Assessing articulation and discrimination of votes revealed distorted pronunciation of a certain number of votes: pronunciation of vocals /I/ and /U/ in certain positions with nasal voices; the substitution of sonic consonants with silent pairs or nasals was present. The pronunciation significantly improved with occasional substitu-

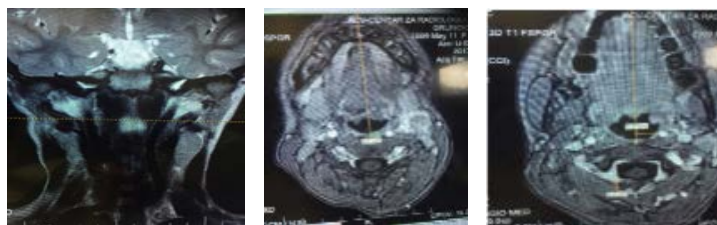

Fig. 1 – Magnetic resonance imaging (MRI) angiography of the head and neck showing an abnormal position of the left internal carotid artery (ICA) extending submucosally to the posterior wall of the pharynx.

cals and consonants by distortion type except nasal /M/, /N/, /Nj/. The substitution of sonic consonants with silent pairs or nasals was present – pronouns: voices /P/ and /B/ substituted by voice /M/; voice /G/ substituted by voice /K/; nasally produced to be perceived in most cases as nasal /N/; voice /D/ substituted by voice /T/; fricatives: /Z/ substituted by voice /S/; /Ž/ substituted by voice /Š/; nasally produced voices /V/, /H/, without voice /R/ with a properly spoken voice /J/; affricates: voice /D/ substituted by voice /Č/; voice /Dž/ substituted by voice /Č/; distorted voice /C/ for nasalization of oral voices; laterals: voice replacement /L/ and /Lj/ by voice /N/; speech intelligibility was significantly impaired.

Having successfully mapped the anatomical variation of the ICA, the possibilities of nasal speech correction by surgery and possible complications applying certain methods of correction of VPI were explained to the parents. In May 2013, the patient was hospitalized in other Clinical Centre and subjected to the surgical treatment of submucosal cleft palate. The postoperative course was neat. Nevertheless, postoperatively VPI with poor speech was persisted. The pediatric examination of the patient's neurological development did however show areflexia, as well as a neat trophic of the upper and lower extremities. A genetic examination further determined clinodactyly of the small toes,

tion of pleisus /B/ nasal /M/; fricatives: /Z/ in most situations substituted by voice /S/, /Ž/ substituted by voice /Š/; affricates: voice /D/ substituted by voice /Č/ in certain combinations, voice /Dž/ substituted by voice /Č/; laterals: replacement of voice /L/ voice /N/ in most speech discourses. Rhythm and tempo of speech were as follows: during the insistence on the proper articulation of voices, occasionally pausing and repetition of syllables could be observed, which could be described as mild dysfunction. The speech melody was partially disturbed. Speech intelligibility was also partially impaired. During spontaneous speech, the girl had worse performance in speech production compared to speech quality during speech therapy. Articulation finding was: incorrect pronunciation of all voices of the mother tongue due to open nasalization, less intensity than before surgery; vocals: slightly distorted vocals /I/ and /U/ especially pronounced in the combination of syllables with nasals; plays: substitution of voice /B/ by voice /M/, voice /D/ by voice /N/ during continuous speech occasionally; fricatives: nasal colored voices /W/, /S/, /Z/; affricates: nasal colored affricates: /Č/, /J/, /Č/, /D/; laterals: nasal voice pronunciation /L/ nasally: proper pronunciation of the voices /M/, /N/, /NJ/. The performance of speech was slightly impaired.

Surgical methods for correction VPI as pharyngoplasty and sphincteroplasty groups are contraindicated in patients with DiGeorge syndrome, due to the risk for severe peri- and postoperative complications. Operation with risk also includes augmentation methods to increase Passavant's thickening. The applying of bucal flaps is more harder and complicated procedure than palatoplasties in treatment of VPI. Surgical methods from the palatoplasty groups, Furlow "Z" intravelar veloplasty, and "Dorrance like flap", include relatively less risk. After consular consideration, it was decided to perform intravelar veloplasty according to Furlow. Intraoperatively, measurement showed that the soft palate is too short and that intra-velar veloplasty "Z" plastic according to Furlow, by elongation, would not provide sufficient length of the soft palate. A harvested mucoperiosteal flap was removed from the hard palate. The "dorrance-like" flap raised to the palatine aponeuroses at the posterior edges of the palatine bones, leaving the oral surface of the bones exposed. The flap raised in this way, just by its repositioning by "sliding" could not provide the necessary retroposition of the soft palate. Comparing the length of the soft palate and the mucoperiosteal palatal flap, the length of raised mucoperiosteal flap of the palate was 160% of the length of the soft palate (Figure 2a). We turned over raised mucoperiosteal palatal flap (Figure 2b) over the patient's short palate and reached the length of the flap for contact with Passavant fold. This mucoperiosteal palatal flap lacks muscle and active mobility. Its motility is achieved by fixing the mucoperiosteal flap to the mobile, short soft palate and uvula with the individual stitches (Figures 2c and 2d). In that way, we provided safely and effectively anatomical prerequisites for speech recovery and rehabilitation (Figure 3). This described surgery method,

the application of the "turn over" palatal mucoperiosteal flap in the VPI treatment, caused subjective and objective improvement in the patient. After six month postoperatively, a reduction of hypernasality, and slightly better and clearer speech of the last palate consonants were recorded. The speech recording one year after the surgery indicated that the speech recovery of the patient progressed neatly.

Discussion

Because our patient with DiGeorge syndrome had anatomic variation of the topographic position of the left ICA, we made a more detailed analysis of the possible surgical methods for VPI treatment⁸, and choose the most optimal technique due to possible intraoperative complications (ACI injury, dramatic bleeding, and the need for ligation of ACI in a very small and inaccessible operating place for intervention), as well as postoperative complications (scarring and possible partial Philip puncture of the ACI). It was estimated that augmentation methods such as pharyngoplasty and sphincteroplasty were contraindicated in this patient. Surgical methods (palatoplasty) for the correction of VPI related to elongation or retroposition of the soft palate (Furlow) could be applied. However, intraoperatively, a scarred and short soft palate is encountered, which did not allow sufficient mobilization and elongation of the soft palate, leaving only the palatal mucoperiosteal flap. Exposed palatine bones and short palate was covered by mucosal tissue, without cystic formations. We did not find in the available literature that anybody applied such palatal mucoperiosteal "turn over" flap for treatment of incomprehensible speech or for any other kind of reconstruction.

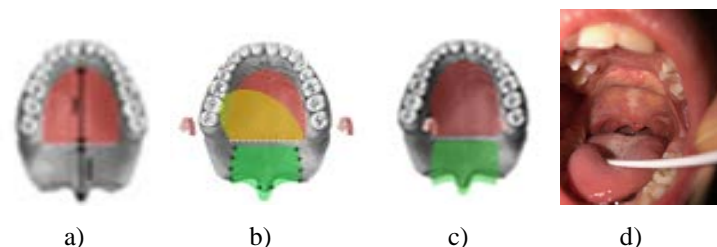
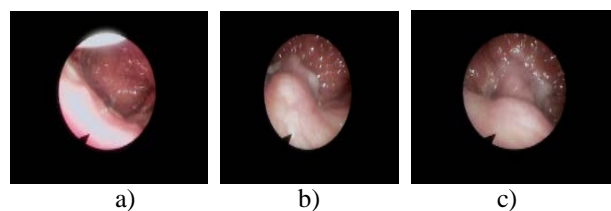


Fig. 2 – a) The ratio of lengths of raised mucoperiosteal flap of the palate and the soft palate; b) Turned over the raised mucoperiosteal palatal flap; c) The soft palate with fixed mucoperiosteal palatal flap; d) The soft palate two months after turnovered mucoperiosteal palatal flap applying.



**Fig. 3 – Nasopharyngoscopy findings after operation:
a) Passavant fold formed;
b) Contact of newly formed uvula with Passavant;
c) Contact of newly formed uvula during ingestion.**

Conclusion

New anatomical structure, obtained by the presented surgical method, caused subjective and objective improvements in the clinical picture of the patient with DiGeorge syndrome. Six months after operation, a reduction of hypernasality, slightly better and clearer speech of the last palate consonants were recorded. The finding was even better after the next six months of follow-up. Because of that, we consider that the mucoperiosteal palatal flap can be easily, successfully and maximally safely applied in the resolution of

VPI in patients with DiGeorge syndrome where there is an aberrant submucosal position of the ICA. We also recommend this “turn over” mucoperiosteal palatal flap as the flap of choice for treatment patients with atopic position of the ICA.

Acknowledgement

We are very grateful to Prof. Slobodan Mitrović, MD, PhD, otorhinolaryngologist – phoniatician, who gave us photos of nasopharyngoscopy.

REFERENCES

1. *Swillen A, Vogels A, Devriendt K, Fryns JP.* Chromosome 22q11 deletion syndrome: update and review of the clinical features, cognitive-behavioral spectrum, and psychiatric complications. *Am Med Genet* 2000; 97(2): 128–35.
2. *Muldoon M, Ousley OY, Kobrynski LJ, Patel S, Oster ME, Fernandez-Carriba S, et al.* The effect of hypocalcemia in early childhood on autism-related social and communication skills in patients with 22q11 deletion syndrome. *Eur Arch Psychiatry Clin Neurosc* 2015; 265 (6): 519–24.
3. *Scherer NJ, D'Antonio LL, Kalbfleisch JH.* Early speech and language development in children with velocardiofacial syndrome. *Am J Med Genet* 1999; 88 (6): 714–23.
4. *Scherer NJ, D'Antonio LL, Rodgers JR.* Profiles of communication disorder in children with velocardiofacial syndrome: comparison to children with Down syndrome. *Genet Med* 2001; 3(1): 72–8.
5. *Eliež S, Palacio-Espasa F, Spira A, Lacroix M, Pont C, Luthi F, et al.* Young children with Velo-Cardio-Facial syndrome (CATCH-22). Psychological and language phenotypes. *Eur Child Adolesc Psychiatry* 2000; 9(2): 109–14.
6. *Solot CB, Knightly C, Handler SD, Gerdes M, McDonald-McGinn DM, Moss E.* Communication disorders in the 22Q11.2 microdeletion syndrome. *J Commun Disord* 2000; 33(3): 187–203; quiz 203–4.
7. *Persson C, Niklasson L, Oskarsdóttir S, Johansson S, Jönsson R, Söderpalm E.* Language skills in 5-8-year-old children with 22q11 deletion syndrome. *Int J Lang Commun Disord* 2006; 41(3): 313–33.
8. *Solot CB, Sell D, Mayne A, Baylis AL, Persson C, Jackson O, et al.* Speech-language disorders in 22q11.2 deletion syndrome: Best practices for diagnosis and treatment. *Am J Speech Lang Pathol* 2019; 28(3): 984–99.

Received on February 2, 2021

Accepted on April 6, 2021

Online First April, 2021